

Healing and Sealing Dental Caries: The Paradigm Has Shifted

Edmond R. Hewlett, D.D.S.

This Afternoon's Topics

- Caries Management by Risk Assessment (CAMBRA)
- Remineralization with CPP/ACP
- Restoring carious lesions – some considerations
- Ultraconservative caries removal

Dental Caries Defined (from Hurlbutt & Young, 2014):

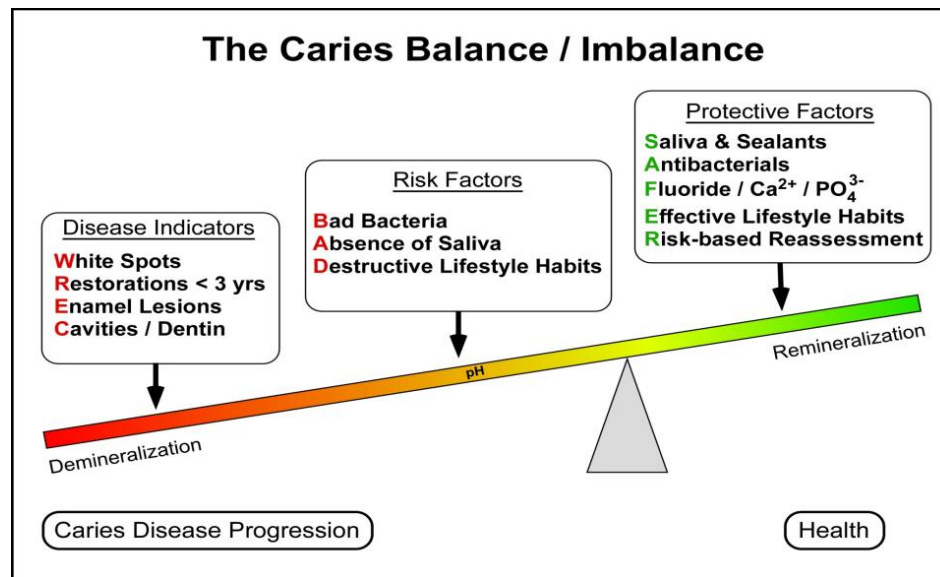
- Dental caries is a multifactorial, biofilm and pH mediated transmissible disease that affects people of all ages and disproportionately affects certain populations at epidemic proportions.
- Simply restoring cavitated teeth does nothing to resolve the disease.

Caries Management, c. 1976

- Diagnosis = DETECTION
 - the earlier, the better
 - visual, sharp explorer, radiograph
- Etiology
 - acid-producing bacteria
- Prevention
 - plaque removal and diet
- Treatment
 - RESTORE cavitated lesions
 - WATCH non-cavitated lesions

Caries – Our Present Understanding

- Balance/Imbalance



- Caries Detection vs. Diagnosis
 - di·ag·no·sis (dī-ig-'nō-səs) *n.* The art or act of identifying disease from its signs and symptoms
 - Tradition Caries Detection (visual, tactile, radiographic)

Caries Risk Assessment (CRA)

- “A formalized process that involves an analysis of the probability that the number, size, or activity of lesions will change over a specified period of time.” (Young, Fontana, & Wolff 2010)

CRA Systems

- California Dental Association (CDA) CRA
 - 24-item questionnaire – disease indicators, risk factors, protective factors
 - Good validity for ID of extreme- and high-risk adult patients (Domejean, et al. 2011)
 - Includes evidence-based clinical management guidelines based on caries risk levels
 - Adult and child versions
- American Dental Association (ADA) CRA
 - Fillable form downloadable from ADA website
 - Checklist of 19 factors associated with caries
 - Adult and child versions
 - No published studies on validity
 - No published ADA guidelines for caries management associated with ADA CRA

- American Association of pediatric Dentistry (AAPD) CRA
 - 14 factors to evaluate for low, moderate, or high risk classification in children
 - Also a CRA form for physicians and non-dentists for 0–3 years of age
 - Includes clinical guidelines that provide evidence-based preventive and treatment recommendations based on the risk level determined
 - Moderate predictive value (Yoon, et al. 2013)
- Cariogram
 - Software program developed at Malmö University in Sweden
 - calculates actual chance to avoid new cavities and offers some guidance in reducing the risk for developing new caries disease
 - Good validity for children and elderly adults per published studies (Campus, et al. 2012; Hansel Petersson et al. 2003)

Remineralization with CPP/ACP

- Enamel white spots – why they matter and what to do about them

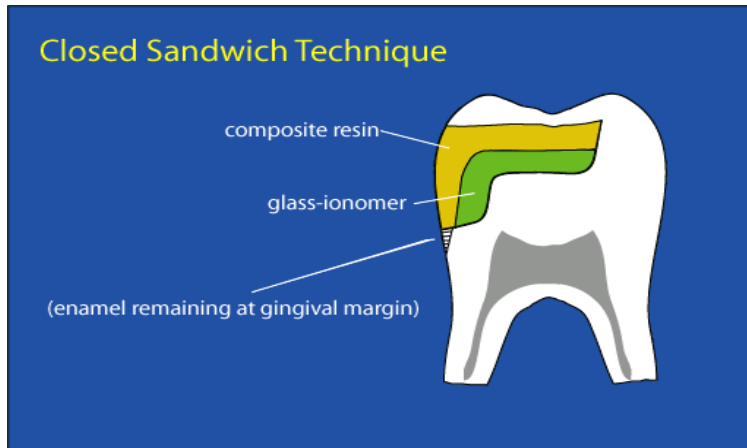
Restoring Caries Lesions – The Role of Glass Ionomer

Sandwich Technique

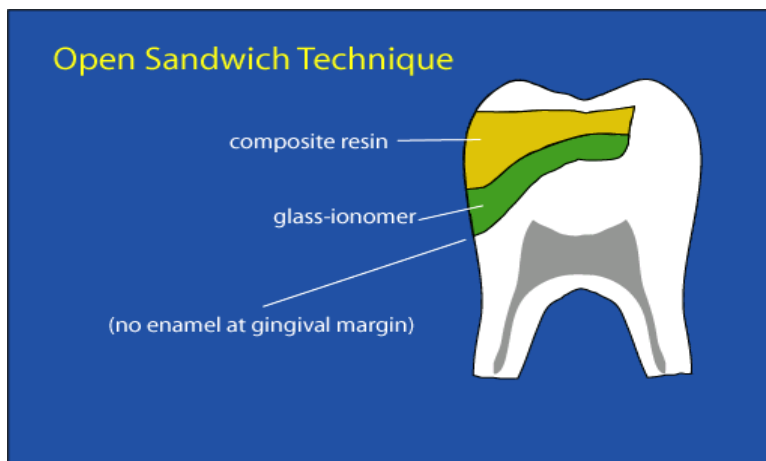
- **Use composite resin and glass ionomer *TOGETHER* in large posterior direct restorations to...**
 - Eliminate post-op sensitivity caused by shrinkage and local gaps in dentin-resin interface
 - Improve seal at margins lacking enamel
 - Reduce restoration placement time

- **Use composite resin and glass ionomer as *FUNCTIONALLY-COMPATIBLE ANALOGUES* for enamel and dentin**
 - Replace DENTIN with GLASS IONOMER
 - No etching → no potential for incomplete resin seal
 - Eliminates technique sensitivity of resin-dentin bonding
 - Chemical bond to dentin → high affinity for dentin surface
 - No shrinkage stress on interface
 - Fluoride release
 - Resistance to microleakage on dentin BETTER than resin bonding
 - BULK PLACEMENT → eliminates time-consuming incremental layering in large cavities
 - Replace ENAMEL with COMPOSITE RESIN
 - Occlusal and proximal wear resistance
 - Translucency/esthetic
 - Best restorative seal on etched enamel

- Persistent occurrence of post-op sensitivity? **“Closed Sandwich”** technique
 - Cover all dentin surfaces with glass ionomer base/restorative
 - Leave as little as 1 mm depth available for composite
 - Etch/prime/bond, and place composite as usual



- No enamel on gingival margin? **“Open Sandwich”** technique
 - Cover all dentin surfaces with glass ionomer base/restorative, AND...
 - Use GLASS IONOMER for the gingival increment of the restoration
 - Place glass ionomer along matrix at gingival margin
 - Stop short of proximal contact area (reserve this area for composite)
 - Glass ionomer exhibits better resistance to microleakage on dentin margins than composite



Ultraconservative Caries Removal – A New Standard?

- “Partial caries removal is...preferable to complete caries removal in the deep lesion, in order to reduce the risk of carious exposure.”
- D. Ricketts, et al. Cochrane Database of Systematic Reviews 2006, Issue 3. Art. No.: CD003808. DOI: 10.1002/14651858.CD003808.pub2
- Frank caries was arrested in sealed restorations
- E. Mertz-Fairhurst, et al. Ultraconservative and Cariostatic Sealed Restorations: Results at Year 10 JADA 1998 (129:55–66)
- “There is substantial evidence that removing all vestiges of infected dentin from lesions approaching the pulp is not required for caries management.”
- V. Thompson, et al. Treatment of Deep Carious Lesions by Complete Excavation or Partial Removal: A critical review. JADA 2008 (139:705-712)

Caries Removal – A Paradigm Shift

- Remove all soft dentin
- STOP when firm/dry to avoid pulp exposure
- DON'T excavate to point of pink, “blushing”
- Seal in remaining bacteria with glass ionomer

References

Campus G, Cagetti MG, Sale S, Carta G, Lingstrom P. Cariogram validity in schoolchildren: a two-year follow-up study. *Caries Res* 2012;46(1):16-22

Domejean S, White JM, Featherstone JD. Validation of the CDA CAMBRA caries risk assessment—a six-year retrospective study. *J Calif Dent Assoc* 2011;39(10):709-15.

Hansel Petersson G, Fure S, Bratthall D. Evaluation of a computer-based caries risk assessment program in an elderly group of individuals. *Acta Odontol Scand* 2003;61(3):164-71

Hurlbutt M and Douglas DA. A best practices approach to caries management. *J Evid Based Dent Pract.* 2014 Jun;14 Suppl:77-86

Maltz M, Garcia R, et al. Randomized trial of partial vs. stepwise caries removal: 3-year follow-up. *J Dent Res.* 2012 Nov;91(11):1026-31.

Mertz-Fairhurst EJ1, Curtis JW Jr, Ergle JW, Rueggeberg FA, Adair SM. Ultraconservative and cariostatic sealed restorations: results at year 10. *J Am Dent Assoc.* 1998 Jan;129(1):55-66.

Ricketts DN, Kidd EA, Innes N, Clarkson J. Complete or ultraconservative removal of decayed tissue in unfilled teeth. *Cochrane Database Syst Rev.* 2006 Jul 19;(3):CD003808.

Thompson V, Craig RG, Curro FA, Green WS, Ship JA. Thompson V, Craig RG, Curro FA, Green WS, Ship JA. *J Am Dent Assoc.* 2008 Jun;139(6):705-12.

Yoon RK, Smaldone AM, Edelstein BL. Early childhood caries screening tools: a comparison of four approaches. *J Am Dent Assoc* 2012;143(7):756-63.

Young DA, Featherstone JD. Caries management by risk assessment. *Community Dent Oral Epidemiol.* 2013 Feb;41(1)

Young DA, Fontana M, Wolff MS. *Current Concepts in Cariology.* Dental Clinics of North America, Vol 54(3), July 2010

Journal of the California Dental Association – CAMBRA-themed issues accessible at <http://www.cdafoundation.org>, search term "cambra":

- February and March, 2003
- October and November, 2007
- October and November, 2011

ehewlett@dentistry.ucla.edu