

*****Handout*****
Etched Porcelain Veneers
By
Harald O. Heymann, DDS MEd

Tooth Preparation

Important! The ultimate key to long-term success with etched porcelain veneers is to use **an intra-enamel preparation**. Research shows that bonds to enamel are far more predictable and durable than those to dentin. (Meiers JC and Young D. Two-year composite/dentin durability. *Amer J Dent* 2001; 14(3): 141-144 and Friedman MJ. A 15-year review of porcelain veneer failure: a clinician's observation. *Compend Cont Ed Dent* 1998; 19:625-636.).

Preparation Design:

- * Facial reduction is approximately 0.5-0.75 mm mid-facially, terminating at the gingival margin with a heavy chamfer and a reduction depth of 0.3-0.5mm (Figure 1). Incisal reduction is typically 1.0-1.5 mm.
- * Facial reduction is best achieved using a series of three horizontal "hemi-preps" so that reduction depths can be seen in cross-section.
- * An incisal lapping preparation is the strongest design (see Figure 1 below), but a simple butt joint with no lapping is the easiest design to prepare.

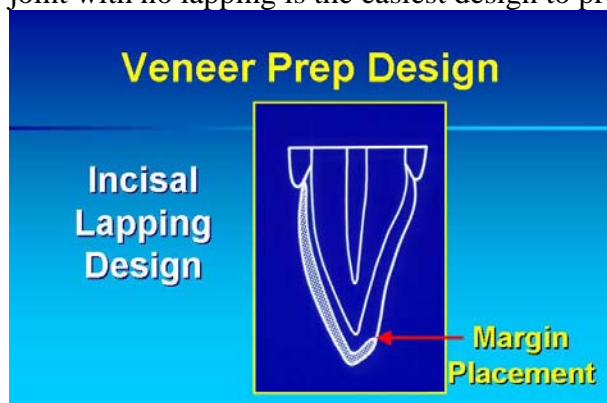

Figure 1

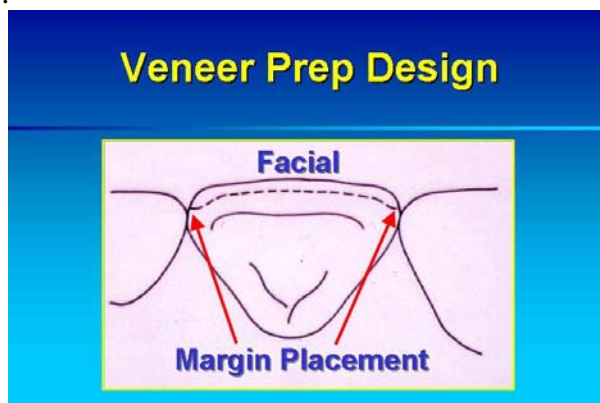


Figure 2

- * If interproximal tooth contact is present, the margins of the preparation are positioned just facial to the contact area to maintain an optimal contact relationship (Figure 2).
- * Interproximal contacts are not stripped or eliminated with this preparation design.
- * Gingival margins are maintained at the level of the crest of the gingival tissue if the discoloration or defects extend into the gingival one-third of the tooth. If the gingival one-third is free from defects, the gingival margin can be placed supra-gingival for optimal tissue health.

Impression

- * If gingival embrasures are wide open, block them out from the lingual to prevent interlocking of the impression material facio-lingually and tearing of the impression.
- * Leave small diameter retraction cords in place. Carefully remove from impression if they are attached.

Temporization

- * If a pre-operative diagnostic wax-up is made, temporaries must be generated based on this wax-up in order to verify the anticipated final veneer contours, speech, and esthetics. On occasion, if no wax-up is indicated, no temporaries are needed with intra-enamel preps.
- * If temporaries are needed, they can best be made using a clear polyvinyl impression material (eg. Template Clear PVS from Clinician's Choice) for pre-op impression and a bis-acryl temporary material attached by spot etching small (~2mm diameter) facial area on each prepared tooth. Keep the clear impression until veneer delivery in case the patient breaks a temporary, and requires a repair.
- * Caution patient to avoid biting with the veneer temporaries. These temps are for looks, not function!

Try-In and Cementation

- * Try in veneers to assess marginal fit and relationship to one another mesially and distally. Minor adjustment to proximal margins can be made atraumatically with a coarse Soflex Disc (3M ESPE).
- * To assess shade, try in a central incisor veneer. Try-in pastes are available, but I prefer water or a water-based gel to best assess esthetics of the veneers. Select value of veneer cement based on try-in. I use the translucent shade of veneer cement (virtually clear) 95% of the time unless significant staining of tooth exists. Opaque cements containing titanium dioxide can kill "esthetic vitality," so be careful in using them. In my opinion, any masking qualities should be incorporated in the veneer itself for best results.
- * After try-in, dry veneer thoroughly before proceeding with bonding. Apply silane to tooth side of clean, uncontaminated veneer.
- * Turn down operatory light prior to bonding the veneers to prevent inadvertent premature curing of the resin bonding components. Bond the two central incisor veneers first. Apply resin bonding agent to etched veneer and etched enamel surfaces, and load veneer with uniform thickness of veneer bonding cement. Seat veneer prior to light curing any of the resin components. Use a light-cured resin cement, not a dual-cured resin cement to avoid future potential discoloration from tertiary amines. Light-cured resin cements are far more color-stable over time.

Finishing and Polishing

- * Use a #12 blade (not 12-B!) in a Bard-Parker surgical handle to remove most of the marginal excess of cured cement. Be careful! Be sure to use a good finger rest and controlled strokes!
- * Using a very fine diamond instrument (flame for facial, oval for lingual), "dress" any marginal areas of the veneer where overhangs, bulbous areas or rough spots exist. Margins should be smooth and confluent with surrounding tooth contours. Adjust the occlusion with an oval diamond instrument.
- * Use a 30-fluted carbide finishing bur to smooth any areas dressed with the diamond to plane the porcelain surfaces and to remove any residual striations produced by the diamond.
- * Use porcelain polishing cups and points (eg. Dialite system from Brasseler USA) to polish any areas that have been adjusted.
- * Caution: patient must avoid hard foods or objects to prevent chipping of veneers. A processed acrylic biteguard is often recommended as well to help protect veneers.

Recommended Instruments and Materials

Tooth preparation: Brasseler USA #856 016 diamond is recommended for the veneer preparation.

Retraction cord: Size O, Ultra-Pak by Ultradent.

Veneer temporaries: Template Clear PVS by Clinician's Choice with bis-acryl temp material of your choice.

Veneer Bonding Cements

-Rely-X Veneer Cement by 3M ESPE

-Nexus by Kerr

-Calibra by Caulk Dentsply

-Ensure by Cosmedent

Veneer finishing and polishing:

-Soflex Discs by 3M ESPE (coarse) for proximal adjustment prior to cementation if needed.

-Fine diamonds by Brasseler USA for dressing margins: flame- #8862 for facial areas; oval- #7379 for lingual areas; ultra-thin flame- 8889 for interproximal areas and incisal embrasures.

-30-fluted finishing bur (#H133UF- Brasseler USA or #9803- Midwest division of Kerr) to plane surfaces contoured by diamond prior to diamond polishing.

-Dialite Porcelain Polishing points and cups by Brasseler USA for final polishing.

Speaker Information:

Harald O. Heymann, DDS MEd

Thomas P. Hinman Distinguished Professor

Department of Operative Dentistry

School of Dentistry

University of North Carolina

Chapel Hill, North Carolina 25799-7450

Bus. Tel. 919-537-3985

Email: harald_heyman@unc.edu

DISCLOSURE

Dr. Heymann has no financial interest in any of the companies whose products are mentioned in this handout, has been a scientific advisor for Clinical Research Dental Co.

Vers. 1-16